

TOTAL THYROIDECTOMY AS PREFERRED OPTION FOR BENIGN DISEASE—OUR EXPERIENCE OF 152 CASES

Ata Ul Lateef¹, Muhammad Sajid², Muhammad Yaqoob³, Sarwat Bibi⁴, Junaid Misbah⁵

¹Assistant Professor of Surgery, Punjab Medical College, Faisalabad.

²Associate Professor of Surgery, Punjab Medical College, Faisalabad.

³Senior Registrar Surgery, DHQ Hospital (PMC), Faisalabad.

⁴Registrar Surgery, DHQ Hospital (PMC), Faisalabad.

⁵Registrar Surgery, DHQ Hospital (PMC), Faisalabad.

ABSTRACT

Background:

Type of study: Experimental.

Study design: Case series.

Place and duration of study: It was conducted in surgical unit-4 DHQ Hospital, Punjab Medical College, Faisalabad from January 2009 to December 2011.

Objectives:

To evaluate the safety of total thyroidectomy for benign disease in terms of permanent complications i.e. Hypoparathyroidism and Recurrent Laryngeal Nerve (RLN) damage.

Methods:

One hundred and fifty two patients with benign enlargement of thyroid gland (Multinodular, euthyroid and toxic goiters, Grave's disease) underwent total thyroidectomy from January 2009 till December 2011. Evaluation of results was done by analyzing the data in SPSS Version-17. Parathyroids were identified pre-operatively and Recurrent Laryngeal Nerve (RLN) traced throughout its course.¹

Results:

Fourteen patients presented with transient post-operative hypocalcaemia (9.2%). Only one patient developed permanent Hypoparathyroidism (0.6%), confirmed by estimating parathormone levels in blood. One patient developed permanent unilateral RLN injury (0.6%). No patient developed bilateral RLN injury (0%). Two patients developed hematoma due to reactionary hemorrhage necessitating re-opening and securing of bleeding vessel (1.2%). Six patients (3.9%) developed serous collection post-operatively and were treated successfully with aspiration alone. There was no mortality (0%).

Conclusion:

Total thyroidectomy (TT), if performed by experienced surgeons is quite safe and preferred option for management of benign thyroid disease to avoid future recurrences.

Keywords: Total thyroidectomy (TT), Hypoparathyroidism, Recurrent Laryngeal Nerve (RLN), Benign Thyroid Disease

Corresponding Author:

Dr. Ata Ul Lateef,

Assistant Professor Surgery,

Punjab Medical College, Faisalabad.

Email: ataullateef@hotmail.com

INTRODUCTION

The extent of thyroidectomy for benign disease is controversial and is determined by desired outcome (risk of recurrence vs. euthyroidism) and surgeon's experience. Long

term follow up including clinical review and yearly TSH estimation is required in patients undergoing total thyroidectomy.²

Total thyroidectomy is currently preferred treatment for Grave's disease and Multinodular goiter. However, some surgeons choose not to perform it owing to associated risk of postoperative Hypoparathyroidism and RLN damage.³

Total thyroidectomy seems to be optimal procedure when surgery is indicated, for benign thyroid disease as it has advantages of immediate and permanent cure with no recurrences.³

Total thyroidectomy for benign thyroid disease was increasingly used in developed countries of the world almost 40 years ago.⁴ Though seen as over hazardous by some because of risk to RLN injury and damage to parathyroids, there is currently a change in surgical practice from subtotal to total thyroidectomy which has no significant effect on rate of permanent complications and helps avoid re-operation in cases of incidentally diagnosed thyroid carcinoma.⁵ In this study we found that after total thyroidectomy done for benign disease, the rate of permanent complications was not significantly higher as compared to international studies, it was rather lower than reported in some studies.^{6,7}

PATIENTS AND METHODS

Inclusion criteria:

In this case series, a total of 152 patients were included who underwent total thyroidectomy for benign disease for different indications of surgery (multinodular goiters, failure of medical treatment to treat Graves Disease, adverse reactions to anti-thyroid drugs, huge goiters with pressure symptoms, and cosmetic).

Exclusion criteria:

Patients with pre-operative diagnosis of thyroid cancer and patients undergoing unilateral lobectomy+isthmusectomy and subtotal thyroidectomy were excluded from the study. Patients with recurrent goiters were also excluded from the study.

All patients underwent pre-operative preparation including antithyroid drugs, where indicated. Pre-operative serum calcium levels and Indirect Laryngoscopy (IDL) was done in all

patients. Preoperative investigations, including thyroid function tests and routine biochemistry, were performed on all patients. Other tests, such as nuclear and ultrasonographic scanning and fine-needle aspiration cytology, were performed selectively.

We opted total thyroidectomy for benign diseases with indication of surgery. All cases were performed by selected team consultant surgeons in DHQ Hospital, Faisalabad from January 2009 to December 2011.

In all of these patients, thyroidectomy was performed through a collar skin incision, flaps were raised using diathermy. All other steps mentioned in literature for conventional thyroidectomy were followed. The operating surgeons were very meticulous in securing the hemostasis. However, either chromic catgut ligature or bipolar diathermy was used for the purpose of securing hemostasis especially when exploring the recurrent laryngeal nerve and parathyroid glands. Recurrent laryngeal nerve was identified on either side and traced throughout its course till its point of entrance into larynx below the ligament of Berry. Dissection and ligation of the multiple vessels on the thyroid capsule was performed to preserve the blood supply of the parathyroids and minimize inadvertent injury to the recurrent laryngeal nerve.

Parathyroid glands were also identified on either side according to their anatomical location, in the vicinity of branches of inferior thyroid artery.

After completion of procedure, it was confirmed that the nerves and the glands have been left intact on both sides and all the macroscopic thyroid tissue removed. The wound was closed over a suction drain in either case.

The record of complications of the procedure was maintained on data sheets and analyzed using SPSS V-17.

RESULTS

Out of 152 cases operated, 117 were female (76.97%) and 35 were male (23.03%). The age range was from 18 to 62 years with median age of 37 years. TT was done after necessary preparation, for multinodular goiters in 128 patients (84.21%) and for Grave's disease in 24 patients (15.79%).

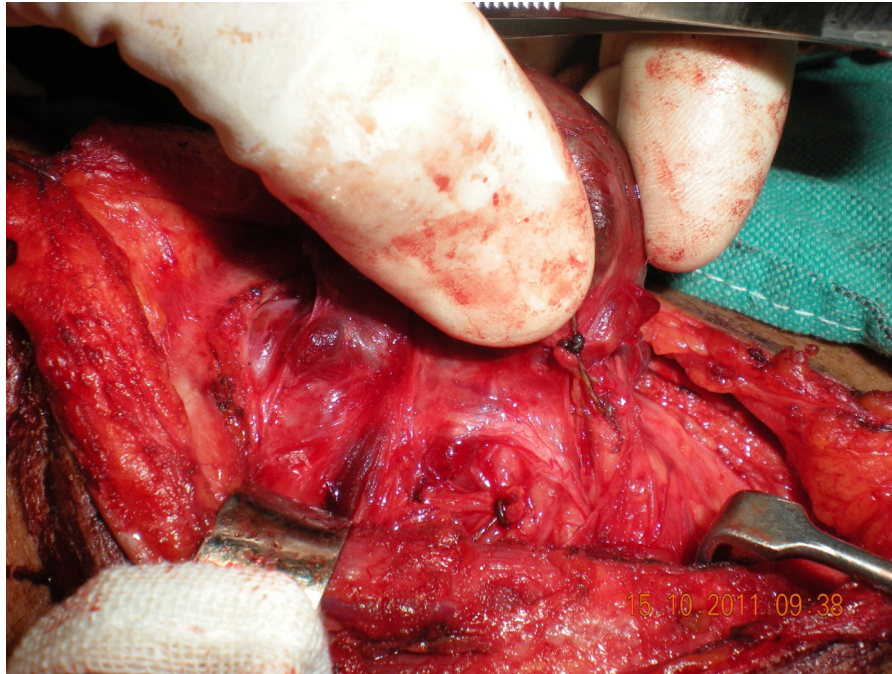


Fig. 1. Recurrent Laryngeal Nerve

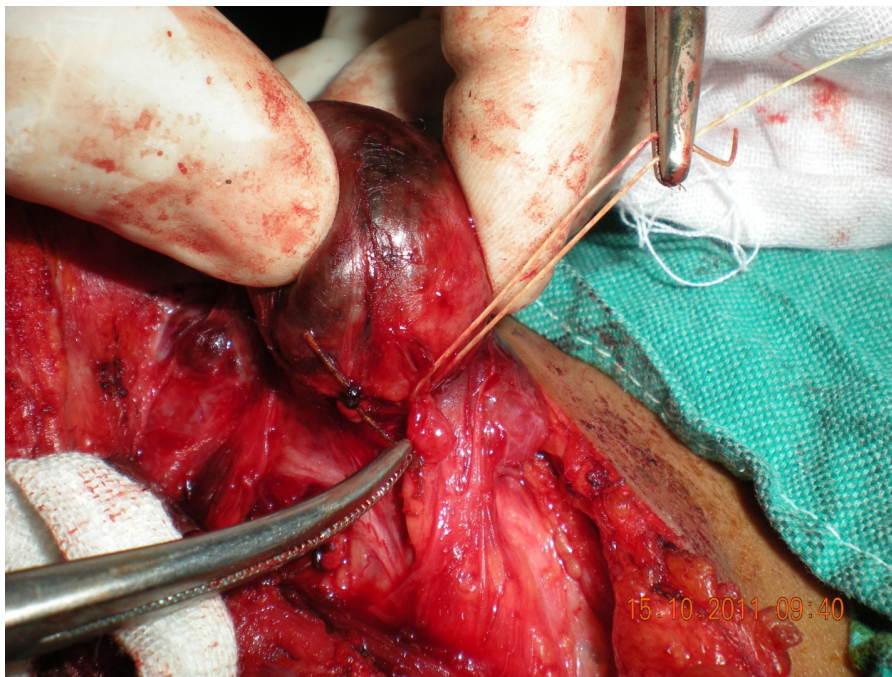

Fig. 2. Parathyroid Gland

Twenty eight patients (18.42%) were experienced to have post-operative complications. Fourteen patients had transient hypocalcaemia (9.2%) which was followed by serial serum calcium estimation and treated with intravenous calcium gluconate. Typically the patients presented 6-12 hours after

surgery with clinical features of hypocalcaemia. Six patients had post-operative hoarseness of voice (3.9%). They were followed by IDL and all except one recovered within two weeks. Six patients had seroma formation (3.9%) and were treated with aspiration. Two patients (1.31%) had neck hematoma

because of reactionary hemorrhage and were treated by re-exploration and ligation of the bleeding vessel. No patient died of the procedure (0%). Only 1 patient remained permanently hypoparathyroid (0.6%) which was confirmed by parathormone levels. One out of 152 patients (0.6%) had permanent unilateral RLN injury while bilateral injury was not reported in any patient (0%). In one patient having permanent Hypoparathyroidism, the damage to parathyroids was due to difficult dissection, but still parathyroids were recognizable. In patient with RLN injury it was continuous bleeding in the area of ligament of Berry which could not be secured by bi-polar diathermy and had to be under-run with a ligature.

DISCUSSION

Total thyroidectomy is an operation that continues to evoke considerable controversy, especially when it comes to benign thyroid disease; TT has not been generally advocated⁸. Some authors have recommended its use for benign disease where recurrent disease (9-43%)⁹ following subtotal thyroidectomy is a significant problem¹⁰. When dealing with multinodular goiter in particular, the surgeon commonly finds that there is no apparently normal thyroid tissue

remaining. He or she must then choose between leaving abnormal thyroid tissue behind and performing sub-total thyroidectomy. The subtotal thyroidectomy carries with it the risk of recurrent disease, which may require subsequent re-operation, whereas total thyroidectomy theoretically has the potential hazards of an increased risk of either permanent Hypoparathyroidism or RLN injury. The incidence of permanent complications after total thyroidectomy varies considerably from center to center. In experienced hands, however, the incidence is acceptably low. In this study we have shown that total thyroidectomy for benign thyroid disease can be performed with minimal complications. Our results were at par with certain international studies¹¹, comparable to others (permanent hypocalcaemia 0.6% vs. 1% and permanent unilateral RLN palsy 0.6% vs. 0-1.3%).¹² We rather experienced a much lower incidence of permanent Hypoparathyroidism (0.6% vs. 3%) and RLN palsy (0.6% vs. 1.85%).^{13,14} We believe that this resulted from the use of the technique of thyroidectomy involving dissection and ligation of the multiple vessels on the thyroid capsule as described above.¹⁵ Some of local and international studies, however, have shown even better results for total thyroidectomy in terms of permanent complications.^{16,17} Table 2 shows the

Table 1. Distribution of complications following total thyroidectomy

Complications	No. of patients	%age
None	124	81.57
Patients with complications	28	18.42
Transient hypocalcaemia	14	9.20
Transient vocal cord paralysis	6	3.90
Seroma formation	6	3.90
Persistent Hypoparathyroidism	1	0.60
Persistent unilateral vocal cord paralysis	1	0.60
Neck Hematoma	2	1.31
Mortality	0	0.00
Bilateral vocal cord paralysis	0	0.00

Table 2. Comparison of results of our study with other studies.

Study	Permanent hypoparathyroidism	Permanent unilateral RLN palsy
Present study	0.6%	0.6%
Aceta P <i>et al.</i> 2011 ¹¹	0.0%	1.5%
Bron LP <i>et al.</i> 2004 ¹²	1.0%	1.3%
Goraya S <i>et al.</i> 2007 ¹³	0.6%	3.0%
Chiang Fu <i>et al.</i> 2006 ¹⁴	3.7%	1.85%
Sheikh IA <i>et al.</i> 2009 ¹⁶	0.3%	0.3%
Barczinski <i>et al.</i> 2011 ¹⁷	0.1%	0.69%

comparison of results of present study with local and international studies which shows that results of our study (when compared with most of the studies referred to) were very convincing.

On the other hand, the risks involved in re-operation for recurrent multinodular goiter are significantly greater than at the first operation. When the entire gland is diseased in patients with multinodular goiter, a bilateral subtotal thyroidectomy, although reducing the bulk of the diseased tissue, is less than optimal treatment and TT is an acceptable alternative to sub-total thyroidectomy in benign goiters if we consider the morbidity associated with recurrent goiters.¹⁸ Leaving a small portion of diseased gland is unlikely to prevent the need for long-term thyroxine replacement therapy, whereas attempts to suppress re-growth of that remaining gland by thyroxine do not guarantee success. In performing a subtotal thyroidectomy it is also possible to leave behind the small posterior-lateral lobule of thyroid tissue that was first described by Zuckerkandl.¹⁹ This tissue often is frequently only recognized while mobilizing the thyroid lobes during TT. Failure to remove embryological remnants such as thyrothymic residue or pyramidal remnants during total thyroidectomy is the major cause of recurrence²⁰.

CONCLUSION

We recommend, therefore, that total thyroidectomy is the procedure of choice for multinodular goiter²¹ or Grave's disease where the entire gland is involved. It must be emphasized, however, that recognition and conservation of the recurrent laryngeal nerve and parathyroid glands must still be paramount when dealing with benign thyroid disease. This can be achieved by capsular dissection using sutures or bipolar diathermy to accomplish the dissection. Ensuring such protection will, on occasion, require that minimal remnant thyroid tissue be left when anatomic vagaries render total excision of the gland less than totally safe.

REFERENCES

1. Ayatec B and Karamercan A. Recurrent laryngeal nerve injury and preservation in thyroidectomy. *Saudi Med J.* 2005; Nov. 26(11): 1746-9.
2. Lal G and Clark OH in Schwartz's Principles of Surgery 9th Ed 2010; pp.1343-1407.
3. Efremidou EI, Papageorgiu MS, Liratzopolus N *et al.* The efficacy and safety of total thyroidectomy in the management of benign thyroid disease: A review of 932 cases. *Can J Surg.* 2009 *Februray*; 52(1): 39-44.
4. Reeve TS, Delbridge L, Cohen A and Crummer P. Total thyroidectomy. The preferred option for multinodular goiter. *Ann Surg.* 1987 *Dec*; 206(6): 782-786.
5. Tezelman S, Borocu I, Senyurek GY *et al.* The change in surgical practice from subtotal to near total thyroidectomy in the treatment of patients with benign multinodular goiter. *World J Surg.* 2009 *March*; 33(3): 400-5.
6. Osmolski A, Frenkiel Z and Osmolski R. Complications in surgical treatment of thyroid disease. *Otolaryngol Pol.* 2006; 60(2): 165-70.
7. Simsek CA, Erdem H, Guzey D *et al.* The factors related with post operative complications in benign nodular thyroid surgery. *Indian J Surg.* 2011 *Jan*; 73(1): 32-6.
8. Erbil Y, Barbaros U, Salmaslioglu A *et al.* The advantage of near total thyroidectomy to avoid post-operative Hypoparathyroidism in benign multinodular goiter. *Lengenbecks Arch Surg.* 2006 *November*; 391(6): 567-73.
9. Ozbas S, Kocak S, Aydintug S *et al.* Comparison of sub-total, near total and total thyroidectomy in the surgical management of multinodular goiter. *Endocrine Journal* 2005; 52(2); 199-205.
10. Friguglietti CU, Lin CS and Kaukasar MA. Total Thyroidectomy for benign thyroid disease. *Laryngoscope* 2003 *October*; 113(10): 1820-26.
11. Acceta P, Accetta I, Accetta AC *et al.* Total thyroidectomy for benign thyroid diseases. *Rev. Col. Bras. Cir. vol. 38 No. 4 Rio de Janeiro July/Aug. 2011.*
12. Bron LP and O'Brien CJ. Total thyroidectomy for clinically benign disease of the thyroid gland. *Br J Surg.* 2004; 91: 569-74.
13. Guraya SY and Eltinay OA. Total Thyroidectomy for Bilateral Benign Thyroid Disease: Safety Profile and Therapeutic Efficacy. *Kuwait Medical Journal.* 2007; 39 (2): 149-152.

14. Chiang FU, Lin JC, Wu CW *et al.* Morbidity after total thyroidectomy for benign disease: Comparison of Grave's disease and Non Grave's disease. *Kaohsiung J Med SC November 2006*; 22(11): 554-559.
15. Fouad Abdelshaheed. Total thyroidectomy for clinically benign thyroid disease: A preferred option with capsular dissection technique. *E J July 2006*; Vol. 25 No. 3.
16. Sheikh IA, Waleem SS, Haider IZ *et al.* Total thyroidectomy as primary elective procedure in multinodular thyroid disease. *J Ayub Med Coll Abbottabad 2009*; 21(4).
17. Barczynski M, Koturek A, Stopa M *et al.* Total thyroidectomy for benign thyroid disease: Is it really worthwhile? *Annals of Surgery, November 2011*; 254(5): 724-30.
18. Riju R, Jadhav S, Kanthaswamy R, Jacob P and Nair CG. Is total thyroidectomy justified in multinodular goitre. *J Indian Med Assoc. 2009 Apr*; 107(4): 223-5.
19. Peizik SL. The place of total thyroidectomy in the management of 909 patients with thyroid disease. *Am J Surg. 1976*; 132: 480-483.
20. Kylie L Snook, Peter LH Stalberg, Stan B Sidhu, Mark S *et al.* Recurrence after total thyroidectomy for benign multinodular goiter. *World Journal of Surgery. 2007*; 31(3): 593-598.
21. Agarwal G and Agarwal V. Is total thyroidectomy the procedure of choice for benign multinodular goiter? An evidence based review. *World J Surgery 2008*; 32(7): 1313-24.

Submitted for publication: 11-02-2012

Accepted for publication
after major revision: 26-03-2012