

## Case Report

# A HIGH GRADE DIFFUSE B CELL LYMPHOMA PRESENTED WITH ISOLATED LARGE SPACE OCCUPYING LESION IN THE FRONTAL LOBE MIMICKING HIGH GRADE GLIOMA OR FUNGAL GRANULOMA CASE REPORT AND REVIEW OF LITERATURE

Saeed Mazher\*, Abdul Ali\*\*, Abdul Khaliq\*\*, Shafatullah\*\*, A. Latif\*\*, Aisha Memon\*\*, Muhammed Usman\*\*

\*Assistant professor, Neurosurgery, Baqai Medical University Hospital Karachi Pakistan.

\*\*Department of Neurosurgery, Baqai Medical University Hospital Karachi Pakistan.

## ABSTRACT

Primary high grade B-cell-type cerebral lymphoma is a rare subtype of primary central nervous system lymphoma. We herein report an unusual case of diffuse B-cell lymphoma in a young lady who presented with a large intracerebral space occupying lesion without extracranial involvement. The notable aspects of this case include the patient was having a short clinical history of symptom onset, rapid neurological deterioration having severe midline shift on imaging and a final histopathological diagnosis was consistent with high-grade diffuse B cell lymphoma after subtotal surgical resection. Extracranial extension of the disease was unremarkable on PET scanning. This case highlights the challenges neurosurgeons face, especially in the emergency setting, when the disease manifests in varied presentations.

**KEY WORDS:** *Rare unusual case, high grade DLBCL, Large Intracerebral Frontal Lobe Lesion, Positron Emission Tomographic scanning, Radiotherapy.*

## INTRODUCTION

Diffuse large B-cell lymphoma is the most common non-Hodgkin lymphoma, making up approximately 30% to 35% of all cases. Our ability to care for patients with diffuse large B-cell lymphoma has improved dramatically during the past 40 years<sup>1</sup>.

In 2007 I had the opportunity to describe my treatment approach for patients with diffuse large B-cell lymphoma in an article published in the journal blood<sup>2</sup>.

Diffuse large B-cell lymphoma (DLBCL) is the most common non-Hodgkin lymphoma. While CHOP (Cyclophosphamide, Doxorubicin, Vincristine and Prednisone) was the standard combination chemotherapy for 25 years, the incorporation of the CD20 antibody rituximab at the beginning of this century has considerably improved the outcome of all patients with DLBCL: Depending on the prognostic subgroup, only half to one-third of the patients die of their DLBCL compared to pre-rituximab era.

Treatment is usually tailored according to the individual risk profile of a Diffuse Large B Cell Lymphoma patient according to the International Prognostic Index (IPI)<sup>3</sup>. There are several subtypes of Diffuse Large B Cell Lymphoma that may affect the prognosis and treatment protocols. As DLBCL that only affect the brain is called Primary Central Nervous System Lymphoma and treated differently that DLBCL that affect areas outside the brain.

It is worth to emphasize the significance of other cases reported in the literature, such as primary dural involvement by diffuse large B-cell lymphoma is extremely rare<sup>4</sup>. There is also one report published to reveal subdural involvement. Another 77years old patient presented with an isolated primary central nervous system lymphoma (PCNSL) of the

*Corresponding Author:*

Saeed Mazher

Assistant professor, Neurosurgery,

Baqai Medical University Hospital Karachi Pakistan.

Email: drbnemaryem@gmail.com

fourth ventricle without extra cranial involvement.<sup>5</sup>

Our objective is to highlight the significance of prompt mandatory surgical intervention to establish early tissue diagnosis which can help in further definitive treatment in terms of adjuncts as chemo radiotherapy to uplift the patient's quality of survival with consideration of decreased morbidity and mortality.

## CASE REPORT

### *History and Presentation*

A 28 year old lady Fareeda presented with the symptoms of double vision, head ache for about one month. Since last week she had been experiencing vomiting and walking difficulty, which was so severe that she got herself admitted under neurosurgical care through the emergency department after getting her Magnetic Resonance Imaging done.

After admitting under neurosurgical care, prophylactic antiepileptic Levetiracetam started along with osmotic diuretic and steroids to decrease the vasogenic edema and mass effect associated with the lesion.

On neurological examination, markedly thin lean lady having right sided partial ptosis and papilloedema. She was able to move her all four limbs with grade -4/5 power having both plantars upgoing. She was vitally stable and systemic review was normal. Rest of the examination was unremarkable.

On Magnetic Resonance imaging she was found to have a large intracranial lesion measuring approx 4x5cm in the frontal lobe on right side causing severe midline shift. Thorough workup was performed in terms of surgical planning. Blood biochemistry including clotting profile and urea creatinine and electrolytes were performed and found in normal range. In addition HIV screening was done which revealed negative result.

Five packed cells and five fresh frozen plasma cells were requested with a preoperative plan to perform the near total excision. The laboratory workup regarding patient's Lactate dehydrogenase levels found within normal limits i.e 275u/l. After subtotal resection, histopathology revealed high grade Diffuse Large B-cell Lymphoma, her PET scan was done which showed no extra cranial involvement.

Soon after surgical intervention patient remained in the Intensive care unit for about two days. As the duration of surgery was about three to four hours initially patient was given sedative and paralyzing agents to avoid peak episodes of raised intracranial pressures. While in the next 24 hours she was well neurologically hence her air way was maintained and endotracheal tube was removed. Surgical wound care was done on regular basis. She showed uneventful recovery and stepped down to Neurosurgical department.

### *Intervention*

Preoperatively subtotal resection was planned. Therefore right sided transcortical frontal approach was performed. Intra-operatively after identification of grayish abnormal brain tissue in the middle and inferior frontal lobe initially biopsy was taken followed by subtotal resection with caution to avoid an entry inside the ventricular system.

Under general anesthesia with specific neuro-protective protocol, right sided pterional craniotomy was performed considering all aseptic measures. Afterwards dura was open in flap fashion having base towards sphenoid sinus after induction of all measures to decrease the intracranial pressure. Cortical incision was given. Arachnoid opened with consideration of preserving normal vessels. After identification of the lesion by the help of biopsy brain needle at the depth of 1.5cm the intra-cerebral lesion was targeted proper biopsy was taken and subtotal resection was done under operating microscope, with consideration of minimal damage to the normal tissue of brain. Most importantly complete resection was avoided because of the anticipation of unwanted ventricular access. Meticulous hemostasis was done. The abnormal brain tissue was sent for the histopathology. It was clearly reported as high grade B-cell lymphoma with stains revealed as CD20 positive and Ki 67 approximately 60 to 70%

Microscopic examination revealed a highly cellular neoplastic lesion composed of sheets of large size atypical lymphoid cells invading into the glial tissue. These neoplastic cells had moderate amount of amphophilic cytoplasm and markedly pleomorphic, hyperchromatic to vesicular nuclei with prominent nucleoli and showed brisk mitotic activity. Perivascular

lymphoid cuffing and areas of necrosis were also seen (Figures 1 and 2).

The neoplastic population expressed diffuse membranous positivity for Pan B (CD20) and negative expression for Pan T (CD3) immunohistochemical (IHC) stains. Ki-67 (Mib-1) index was high (approximately 70%). Glial Fibrillary Acid Protein (GFAP) IHC stain only highlighted scattered residual glial tissue (Figure 3).

After uneventful recovery patient remained in the Intensive care unit for about 48hrs with special monitoring and aggressive supportive therapy in terms of sedation and paralysis. After 24 hrs she was weaned off from the ventilator support with complete recovery of consciousness. Then she was stepped down to Neurosurgery department. She remained well on antibiotic and anticonvulsant therapy along with tapering doses of osmotic diuretic and steroids. She was discharged to oncology department where the further definitive management was planned after performing the PET/CT scans and subsequent staging. It was reported as isolated intensely FDG avid lesion in the brain measuring 55mm in AP direction, 45mm in transverse, 47mm in craniocaudal direction and rest of the distant body systems uptake were negative.

#### *Post intervention course*

She remained in the hospital for thirteen days. After ten days her alternate stitches were removed wound was completely normal without signs of inflammation. After further one week on review visit all the stitches were removed. She has been improving on radiotherapy on planned review visits.

In follow up visits the patient was improving neurologically after initial planned radiotherapy cycles recommended by the consultant oncologist.

Moreover specific chemotherapy was in the consideration of treating consultant oncologist, provided the patient's general condition is better in terms of proper intake of nutrition. Initially in the tumor board discussion with oncologist's bone marrow transplant was under discussion which was superseded by PET/CT scanning as it is non invasive and effective to finalize the definitive management Fig 4.

The overall patient's neurological status and quality of life has improved after subtotal removal and radiation therapy.

## DISCUSSION

Diffuse large B cell lymphoma is potentially a fatal disease but also potentially a curable illness<sup>1</sup>. The most important step in the treatment of the patient is proper excision biopsy reviewed by an expert pathologist. The literature review suggested that different chemotherapy regimens have been used with up to mark results. But there is always a room for radiotherapy for bulky lesions which are measuring about 5 to 10cm.

Diffuse large B-cell lymphoma presenting as a brain tumor, with or without meningeal or ocular involvement, is being seen increasingly in HIV-negative patients. Therapy with CHOP-R or with primary radiotherapy has a poor outcome, with a median survival of less than 1 year. It is now clear that treatment regimens that include high-dose methotrexate plus or minus high-dose cytarabine plus or minus consolidative radiotherapy can achieve long-term, disease-free survival in 30% to 50% of patients, with the best results in younger patients.<sup>6</sup> Our team tries to avoid radiotherapy in the primary treatment regimen to reduce the risk of the development of dementia in long-term survivors. This is a particularly serious problem in patients who are treated after 60 years of age. However, in patients in whom primary chemotherapy regimens fail, radiotherapy provides an important palliative option.<sup>7</sup>

While in comparison studies revealed controversy regarding the place of radiotherapy in the management of patients with diffuse large B-cell lymphoma who have sites of bulky disease at presentation. The definition of bulky disease has varied from 5 to 10 cm in different reports. Some physicians believe that a patient, who achieves a complete remission with a rituximab-containing regimen, particularly if defined by negative results on a positron emission tomographic (PET) scan, does not require consolidative radiotherapy to sites of bulky disease. However, a recent report from

MD Anderson Cancer Center found that radiotherapy after CHOP-R chemotherapy improved 5-year progression-free survival (90% vs 75%) and overall survival (91% vs 83%) in patients with all stages of disease.<sup>8</sup>

Patients received radiotherapy to sites of initially bulky disease after the completion of chemotherapy. Radiotherapy seemed to eliminate the anticipated negative prognostic impact of bulky disease.<sup>9</sup>

I still offer radiotherapy to most patients with sites of bulky disease (ie,  $\geq 10$  cm) regardless of the initial stage of disease. An equivocal PET scan result at the completion of treatment would make me more likely to administer the radiotherapy.<sup>10</sup>

Diffuse large B-cell lymphoma is one of the most consistently PET-avid lymphomas.<sup>11</sup> The standard uptake value (SUV) is typically high, with most lymphomas having an SUV<sub>max</sub> greater than 10 and many having an SUV<sub>max</sub> greater than 20. PET scans improve the accuracy of staging, with as many as 20% to 40% of patients having their stage altered after the performance of a PET scan.<sup>12-15</sup> Perhaps the most important contribution of PET scans to current management of patients with diffuse large B-cell lymphoma is in documenting complete remission. It has become clear that PET scans are more accurate than CT scans in proving complete remission and that a negative PET scan result has the greatest impact in predicting progression-free and overall survival.<sup>16-20</sup> In fact, current restaging guidelines specify that a negative PET scan result is a key factor in documenting complete remission—something that is particularly useful in patients who have a residual mass on CT scan.<sup>21</sup>

While reviewing the literature it has been confirmed that the biopsy for such patients is mandatory and detrimental moreover approach regarding providing the chemotherapy or radiotherapy can be adjustable. In addition due importance is being given to PET/CT scanning for definitive treatment and follow up. As in our case report radiotherapy was initially instituted with future plan of chemotherapy infusions with or without methotrexate depending upon the involvement of craniospinal axis.

There is a documented role of bone marrow transplant in specific cases, this report has limitations to further elaborate about the details

regarding bone marrow biopsy and transplant as our patient had a atypical presentation of isolated intra parenchymal lesion without evidence of extra cranial extension. In comparison to do the near total or total excision, subtotal resection was contemplated just to avoid unnecessary entry in the ventricular system, which could have further deteriorated the clinical neurology of an already compromised young patient with severe midline shift on imaging. It has been well seen in the practice and documented in the literature that while performing the transcortical approaches undue access inside the ventricular system may lead to ventriculitis and meningitis which can result in increasing the morbidity and mortality of patients.

## CONCLUSION

It has become clear that it is a rare entity we come across high grade diffuse large B-cell lymphoma as primary central nervous system involvement. There are different clinicopathologic syndromes that should not all have identical treatment. The unique part of the case is the clinical presentation and preoperative deception of high grade glioma which was proved later histo-pathologically a wrong perception. The interesting part of this case was prompt and safe subtotal resection in terms of decreasing the morbidity and imparting the focused primary central nervous system lymphoma treatment protocols considering multidisciplinary approach management by neurosurgery, histopathology and oncology disciplines.

## ACKNOWLEDGMENT:

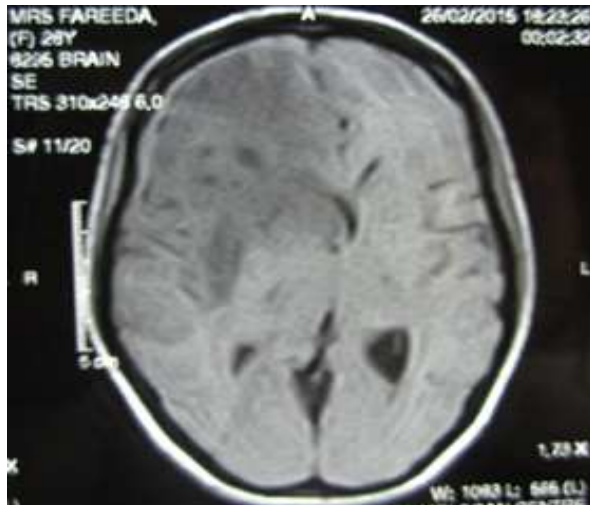
The authors are grateful to Muhammed Imran Zulfikar Hiistopathologist and Syed Ali Muhammad Assistant Manager Histopathology and Training coordinator Clinical Laboratories Agha Khan University Hospital for help in the processing Histopathological pictures and relevant details.

Address to correspondence: Dr. Saeed Mazher Assistant Professor The Baqai University Hospital III-B,1/8 Nazimabad Karachi-18. Email dribnemoryem@gmail.com

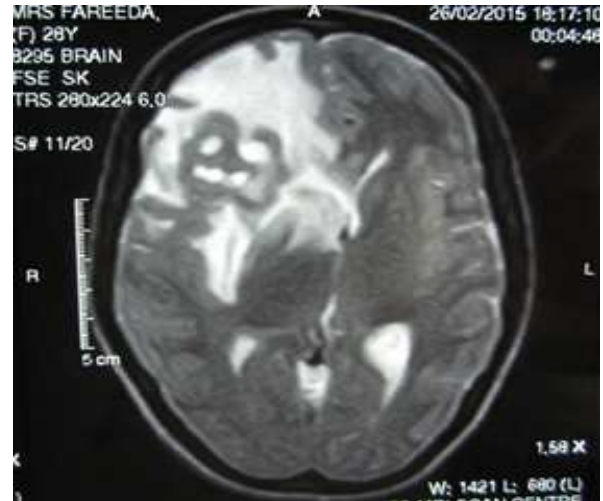

*Pre-surgical Intervention Magnetic Resonance Imaging*

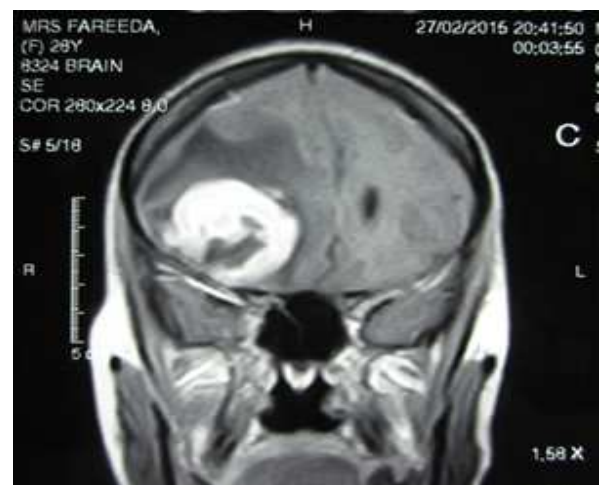
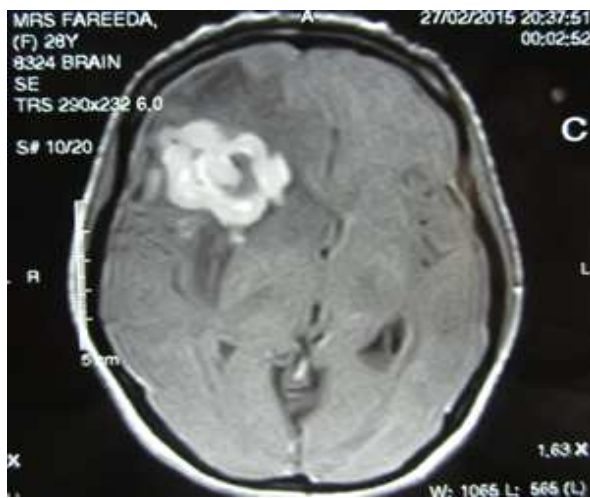**T1W Image**



**T2W Image**

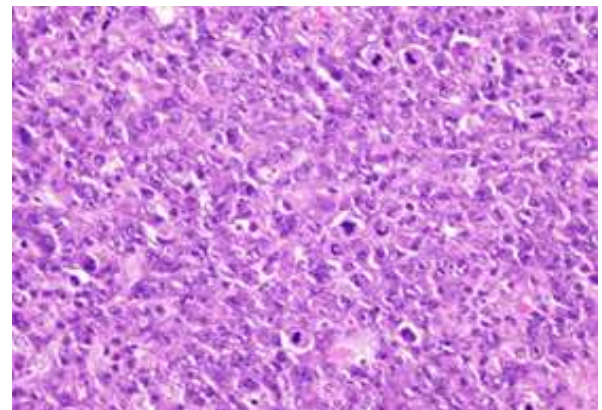
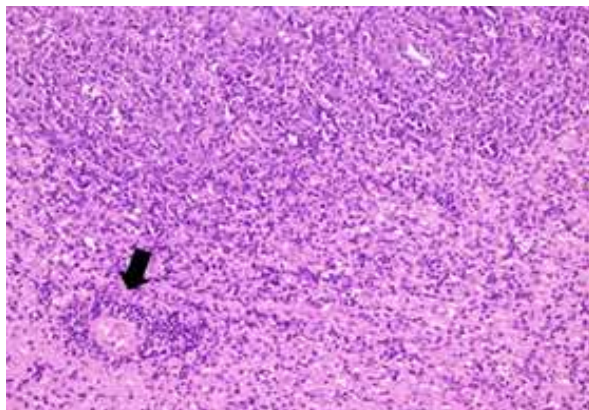


**Contrast Images**



**Fig 1**

**Fig 2**



**Figure1.**

Diffuse sheets of large atypical cells infiltrating into glial tissue. Arrow indicates perivascular lymphoid cuffing i.e. the tumor cells are concentrated and concentrically arranged around a blood vessel. (H&E stain, 200x magnification).

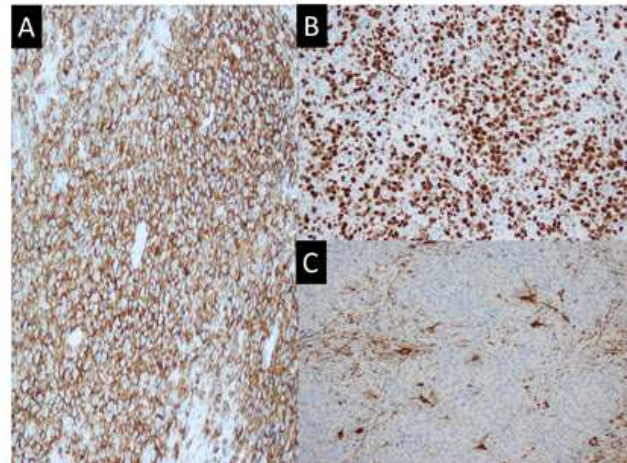
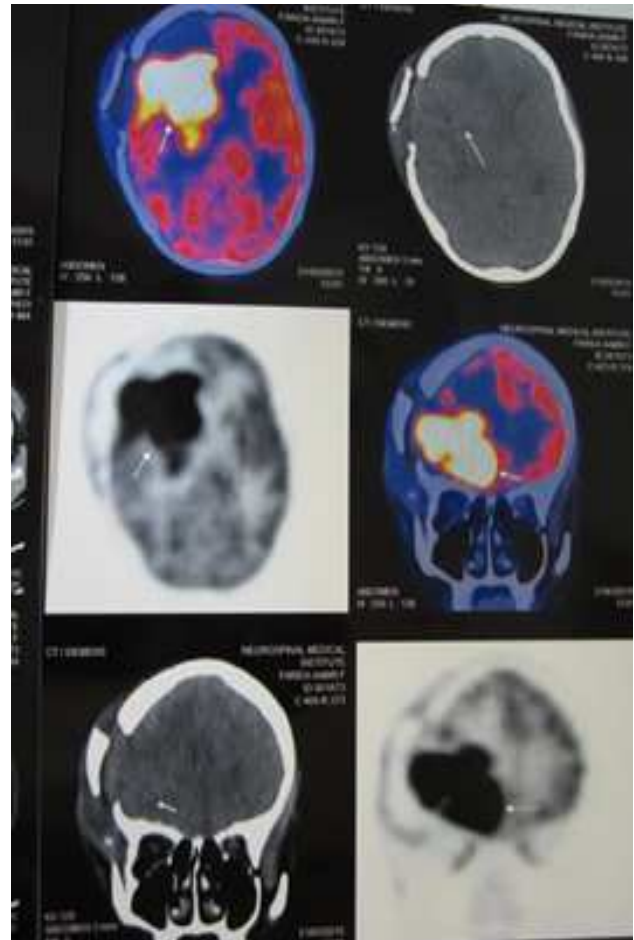
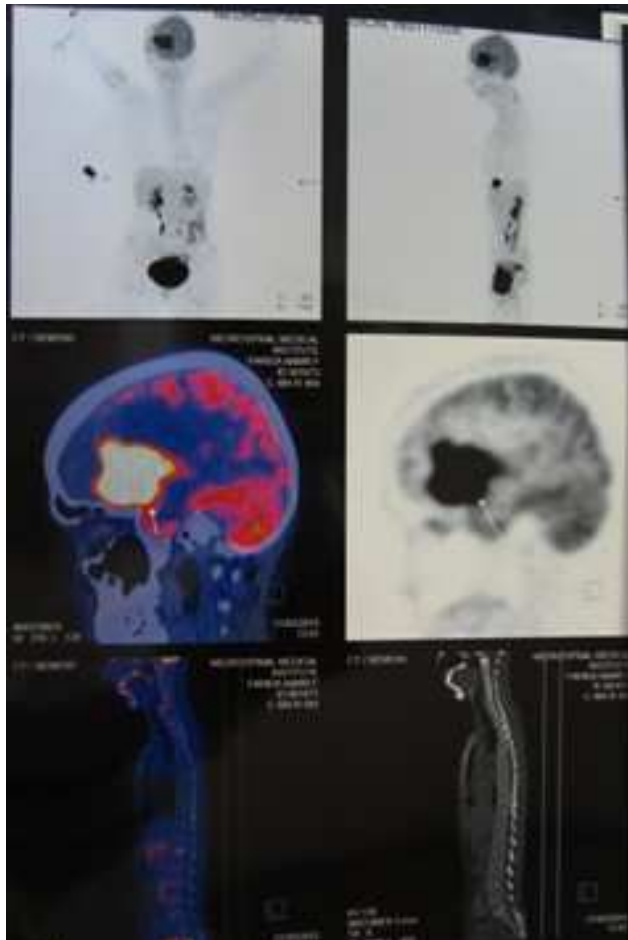
**Figure2.**

High power view of large size neoplastic cells showing marked pleomorphic nuclei with prominent nucleoli and brisk mitotic activity. (H&E stain, 400x magnification).

**Figure 3.**

Immunohistochemical profile. A) Diffuse

membranous positivity of Pan B (CD20) stain, B) High Ki-67 (Mib-1) index, evident as strong nuclear staining and C) GFAP stain highlighting scattered glial cells.

**Fig 4: Post surgical PET/CT Scan.**



## REFERENCES

1. James O. Armitage. Approach to Patients with Diffuse Large B-Cell Lymphoma Mayo Clin Proc. 2012 Feb; 87: 161–171.
2. Armitage J.O. How I treat patients with diffuse large B-cell lymphoma. Blood. 2007;110:29–36.
3. Kubuschok B<sup>1</sup>, Held G, Pfreundschuh M. Management of Diffuse Large B-Cell Lymphoma (DLBCL) Cancer Treat Res. 2015;165:271-88. doi: 10.1007/978-3-319-13150-4\_11.
4. Sacho RH, Kogels M, du Plessis D, Jowitt S, Josan VA Primary diffuse large B-cell central nervous system lymphoma presenting as an acute space-occupying subdural mass. J Neurosurg. 2010;113:384-7. doi: 10.3171/2010.2.JNS091554.
5. Liao CH, Lin SC, Hung SC et al. Primary large B-cell lymphoma of the fourth ventricle. J Clin Neurosci 2014 ;21:180-3. doi: 10.1016/j.jocn.2013.02.036. Epub 2013 Sep 5.
6. Ferreri A.J. How I treat primary CNS lymphoma. Blood. 2011;118:510–522.
7. Khimani N.B., Ng A.K., Chen Y.H., Catalano P., Silver B., Mauch P.M. Salvage radiotherapy in patients with recurrent or refractory primary or secondary central nervous system lymphoma after methotrexate-based chemotherapy. Ann Oncol. 2011;22:979–984.
8. Phan J., Mazloom A., Jeffrey Medeiros L. Benefit of consolidative radiation therapy in patients with diffuse large B-cell lymphoma treated with R-CHOP chemotherapy. J Clin Oncol. 2010;28:4170–4176.
9. Pfreundschuh M., Kuhnt E., Truemper L. 6-Year follow-up of the MINT study suggests a role for radiotherapy to bulky disease. Ann Oncol. 2011;22(suppl 4)
10. Dorth J.A., Chino J.P., Prosnitz L.R. The impact of radiation therapy in patients with diffuse large B-cell lymphoma with positive post-chemotherapy FDG-PET or gallium-67 scans. Ann Oncol. 2011;22:405–410.
11. Tsukamoto N., Kojima M., Hasegawa M. The usefulness of (18)F-fluorodeoxyglucose positron emission tomography ((18)F-FDG-PET) and a comparison of (18)F-FDG-pet with (67)gallium scintigraphy in the evaluation of lymphoma: relation to histologic subtypes based on the World Health Organization classification. Cancer. 2007;110:652–659.
12. Seam P., Juweid M.E., Cheson B.D. The role of FDG-PET scans in patients with lymphoma. Blood. 2007;110:3507–3516.
13. Wirth A., Seymour J.F., Hicks R.J. Fluorine-18 fluorodeoxyglucose positron emission tomography, gallium-67 scintigraphy, and conventional staging for Hodgkin's disease and non-Hodgkin's lymphoma. Am J Med. 2002;112:262–268.
14. Elstrom R.L., Leonard J.P., Coleman M., Brown R.K. Combined PET and low-dose, noncontrast CT scanning obviates the need for additional diagnostic contrast-enhanced CT scans in patients undergoing staging or restaging for lymphoma. Ann Oncol. 2008;19:1770–1773. [PMC free article]
15. Specht L. 2-[18F]fluoro-2-deoxyglucose positron-emission tomography in staging, response evaluation, and treatment planning of lymphomas. Semin Radiat Oncol. 2007;17:190–197.
16. Jerusalem G., Beguin Y., Fassotte M.F. Whole-body positron emission tomography using 18F-fluorodeoxyglucose for posttreatment evaluation in Hodgkin's disease and non-Hodgkin's lymphoma has higher diagnostic and prognostic value than classical computed tomography scan imaging. Blood. 1999;94:429–433.
17. Spaepen K., Stroobants S., Dupont P. Prognostic value of positron emission tomography (PET) with fluorine-18 fluorodeoxyglucose ([18F]FDG) after first-

- line chemotherapy in non-Hodgkin's lymphoma: is [18F]FDG-PET a valid alternative to conventional diagnostic methods? *J Clin Oncol.* 2001;19:414–419.
18. Mikhaeel N.G., Timothy A.R., Hain S.F., O'Doherty M.J. 18-FDG-PET for the assessment of residual masses on CT following treatment of lymphomas. *Ann Oncol.* 2000;11:147–150.
  19. Naumann R., Vaic A., Beuthien-Baumann B. Prognostic value of positron emission tomography in the evaluation of post-treatment residual mass in patients with Hodgkin's disease and non-Hodgkin's lymphoma. *Br J Haematol.* 2001;115: 793–800.
  20. Dupuis J., Itti E., Rahmouni A. Response assessment after an inductive CHOP or CHOP-like regimen with or without rituximab in 103 patients with diffuse large B-cell lymphoma: integrating 18 fluorodeoxyglucose positron emission tomography to the International Workshop Criteria. *Ann Oncol.* 2009;20:503–507.
  21. Cheson B.D., Pfistner B., Juweid M.E. Revised response criteria for malignant lymphoma. *J Clin Oncol.* 2007;25:579–586.

Submitted for publication:	05.11.2015
Accepted for publication:	30.11.2015

The sin which makes you sad and repentant is more liked by Allah than the good deed which turns you arrogant.

One who rushes madly after inordinate desire, runs the risk of encountering destruction and death.

An ignorant person will always overdo a thing or neglect it totally.

. People in this world are like travelers whose journey is going on though they are asleep. (Life's journey is going on though men may not feel it ).

Knowledge and wisdom are really the privilege of a faithful Muslim. If you have lost them, get them back even though you may have to get them from the apostates.

Value of each man depends upon the art and skill which he has attained.

***Hazrat Ali (Karmulha Wajhay)***