

Case Report

SURGICAL CORRECTION OF LONG STANDING 49 YEARS OLD TRAUMATIC ARTERIOVENOUS FISTULA

Muhammad Jamil* Rashid Usman*

*Department of Vascular Surgery, Combined Military Hospital, Lahore Cantt.

ABSTRACT

Traumatic arteriovenous fistula (AVF) is the most fascinating and misdiagnosed complication of vascular trauma resulting from an abnormal communication between an artery and a vein. We present a 69 year old retired soldier who suffered a gunshot wound in 1965 war and has developed disparity in limb size which has grown over the years. He complained of pain, varicosities and stasis dermatitis of leg. He was misdiagnosed for years as a case of varicose veins. Clinical diagnosis of traumatic AVF between femoral artery and vein, was made; which was confirmed by Doppler Scan and Computerised Tomography Angiogram (CTA). Open surgical excision of the fistula was done along with venous patchplasty of artery. Patient had an uneventful recovery and was discharged home with monthly follow up for 6 months. We want to highlight the importance of clinical examination and high index of suspicion for traumatic AVF in all those patients who present with venous varicosities and have a history of trauma in past.

KEYWORDS: Trauma, arteriovenous fistula, varicose veins, venous dermatitis

INTRODUCTION

Vascular injuries are on the rise in the third world countries as a result of road side accidents, assault, war and terrorism. Traumatic AVFs usually result from missed vascular injuries and mostly found in femoral and popliteal arteries. They are more common in penetrating vascular trauma (90%) than blunt vascular trauma (10%)¹. In developed countries the leading causes of such fistulae are complications resulting from endovascular procedures and iatrogenic trauma. Undiagnosed and untreated traumatic AVF in lower limb can cause aneurysmal dilation of vein and artery, congestive heart failure, venous hypertension, varicosities, distal ischemia, limb size disparity, stasis dermatitis, limb oedema and venous ulceration²⁻⁴. Clinical presentation of acquired AVF is based on the nature of the arterial trauma, the anatomical location, diameter of involved vessels and duration of the arteriovenous communication. Diagnosis is made on the basis of history, clinical findings, Doppler scan and CTA.

Open surgical repair of these lesions can be challenging due to the elevated venous pressure and surrounding fibrosis. To the best of our knowledge, we report this first ever successful surgical repair in Pakistan, of a complex long standing traumatic AVF presenting 49 years after the initial injury.

CASE REPORT:

A 69-years old retired soldier was referred to the vascular surgery department of Combined Military Hospital Lahore as a case of old deep vein thrombosis and long standing varicosities of left lower limb. Careful history revealed a bullet injury to the left thigh in 1965 war between Pakistan and India. He was treated at a small military hospital and healed well. Since then he complains of disparity in lower extremity size. The left limb was slowly getting

Corresponding Author:

Muhammad Jamil

Lt Col Muhammad Jamil, Classified Vascular Surgeon, CMH Peshawar

Email: jamilmalik13@yahoo.com

bigger in size over the years. The patient had no history of shortness of breath or any other symptoms of heart failure.

On examination, the left limb was relatively larger than the right. The leg was swollen. The skin was dry, excoriated and pigmented and there were visible varicosities (Figure 1).

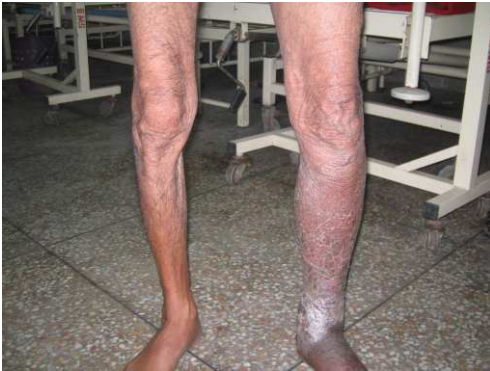

Figure 1: Disparity in limb size. Note the features of venous insufficiency in the leg.

Careful inspection revealed a small, well healed scar in antero-medial aspect of the thigh. There was a palpable thrill and audible bruit in the thigh. The femoral pulse was bounding in character however the distal pulses were weak. A clinical diagnosis of traumatic AVF was made on the basis of history and examination.

Doppler scan of the lower limb suggested a large AVF between superficial femoral artery and vein. CTA revealed marked dilatation of both the left iliac and femoral arteries and veins. The common iliac vein and inferior vena cava were also dilated and filled early with contrast (Figure 2).

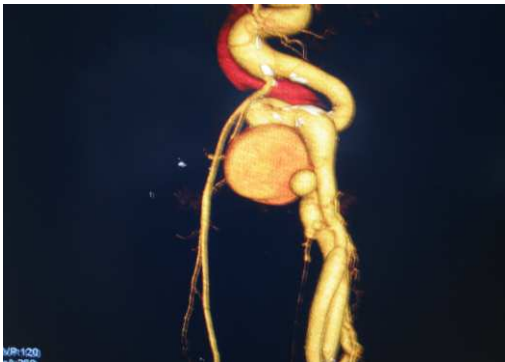


Figure 2: 3D reconstructed CT Angiogram showing the AV fistula and abnormally dilated proximal veins.

We planned open surgical excision of the fistula as we did not have the endovascular facilities in our hospital. The patient was thoroughly investigated and anaesthesia fitness was obtained. Direct surgical exposure of the femoral artery in the groin was performed for proximal control. The fistulous tract was then identified in the superficial femoral artery and vein in the thigh after careful dissection. The fistula was excised, vein was ligated and artery was repaired with venous patch. Heparin was started per-operatively and was continued post operatively to prevent stasis and formation of clots in the dilated iliac veins. Patient made a full recovery with normal distal pulses and Doppler studies revealed no further abnormal arterio-venous communication. The patient was discharged home on 5th postoperative day on warfarin which was continued for 3 months. Follow-up of patients was done weekly in first month and then monthly for next six months.

DISCUSSION

Vascular injuries due to penetrating and blunt trauma can cause significant morbidity and mortality. One of the most commonly undiagnosed complications of vascular trauma is traumatic AVF. Men are much more prone to traumatic AVFs^{2, 3}. Iatrogenic trauma, due to widespread use of catheter-based diagnostic and therapeutic technologies, results in most of traumatic AVFs which are generally benign with a fairly standardized management². The clinical course for AVF due to violent trauma is less predictable, with a wide variation in management practices. Melliore et al. reported that the clinical course of traumatic AVF is related to the relative flow rate of blood across the fistula⁴. The low-flow AVF were usually uncomplicated and close spontaneously while high flow fistulae can cause early cardiac complications, so usually require early surgical correction⁵. Medium-flow AVF are associated with proximal arterial dilatation and generally diagnosed later with or without cardiac complication⁶. Our patient would appear to represent this later group. Aneurysmal dilatation of the artery proximal to a chronic AVF after arterial injury has been well documented⁶⁻⁹.

The vascular injuries with positive hard and soft signs are usually given priority for treatment over those which were not obvious at first presentation. These missed injuries end up with either traumatic AVFs or false aneurysms. The usual history is a small wound in the limb due to either a stab or bullet. This is treated in smaller institutions where vascular and diagnostic facilities are poor. Later on over a period of time, such patients develop clinical features like leg swelling, varicosities, signs of chronic venous insufficiency, distal ischemia, cardiac failure, palpable thrill, audible bruit, and diminished distal pulses with or without signs of chronic arterial and venous insufficiency. Complications of AVFs include skin ulceration, ischemia claudication, steal syndrome, anaemia, renal failure, cardiac overload, and high-output failure^{5,8}.

The diagnosis of traumatic AVF can be made by taking detailed history, clinical examination and using colour Doppler scan and CTA. Direct surgical repair of long-standing traumatic AVF can be challenging due to the obvious venous hypertension and the surrounding scar tissue. The development of endovascular technology may offer potential alternative options for occlusion of these AVF^{10, 11}. In this case, we performed an open repair due to unavailability of endovascular facilities in our setup. Once AVF is repaired, patient should be further followed-up to see the progression or resolution of iliac and femoral arterial dilatation.

CONCLUSION

Vascular injuries should be excluded clinically as well as radiologically especially when the injury is in the vicinity of major vessels. Diagnosis and management of long standing traumatic AVF, is difficult but can be treated surgically which still remains the gold standard in comparison to endovascular procedures in our country.

REFERENCES

1. Robbs JV, Carrim AA, Kadwa AM, Mars M. Traumatic arteriovenous fistula: experience with 202 patients. *Br J Surg* 1994;81:1296-9.
2. Brawley JG, Modrall JG. Traumatic arteriovenous fistulas: Rutherford R, editor. *Vascular surgery*. 6th ed. Philadelphia: Elsevier Saunders; 2005. p. 1619-25.
3. Kotelis D, Klemm K, Tengg-Kobligk H, Allenberg JR, Bockler D. Intermittent claudication secondary to a traumatic arteriovenous fistula. *Vasa* 2007;36:285-7.
4. Mellièrè D, Hassen-Khodja R, Cormier JM, Le Bas P, Mikati A, Ronsse H. Proximal arterial dilatation developing after surgical closure of long-standing posttraumatic arteriovenous fistula. *Ann Vasc Surg* 1997;11:391-6.
5. Weng CF, Wei J, Lee YT, Sue SH, Chuang YC, Chang CY, et al. High-output heart failure resulting from an obscure traumatic arteriovenous fistula. *J Chin Med Assoc* 2008;71:428-30.
6. Ceallaigh PO, Hogan N, McLaughlin R, Bouchier-Hayes D. Popliteal arteriovenous fistula post total knee replacement. *EJVES Extra*. 2004;7:33-5.
7. Amirjamshidi A, Abbassioun K, Rahmat H. Traumatic aneurysms and arteriovenous fistulas of the extracranial vessels in war injuries. *Surg Neurol*. 2000;53:136-45.
8. Robbs JV, Carrim AA, Kadwa AM, Mars M. Traumatic arteriovenous fistula: experience with 202 patients. *Br J Surg*. 1994;81:1296-9.
9. Chen JK, Johnson PT, Fishman EK. Diagnosis of clinically unsuspected posttraumatic arteriovenous fistulas of the pelvis using CT angiography. *AJR Am J Roentgenol*. 2007;188:269-73.
10. Risberg B, Lønn L. Management of vascular injuries using endovascular techniques. *Eur J Surg*. 2000;166:196-201.
11. Katsanos K, Sabharwal T, Carrell T, Dourado R, Adam A. Peripheral endografts for the treatment of traumatic arterial injuries. *Emerg Radiol*. 2009;16:175-84.

Submitted for publication: 04.07.2015

Accepted for publication: 30.09.2015